

Using a hierarchical approach to investigate residual auditory cognition in persistent vegetative state

Adrian M. Owen^{1,2,*}, Martin R. Coleman², David K. Menon², Emma L. Berry¹,
Ingrid S. Johnsrude¹, Jennifer M. Rodd³, Matthew H. Davis¹ and John D. Pickard²

¹MRC Cognition and Brain Sciences Unit, 15 Chaucer Road, Cambridge CB2 2EF, UK

²Wolfson Brain Imaging Centre and the Cambridge Coma Study Group, Addenbrooke's Hospital,
University of Cambridge, Hills Road, Cambridge CB2 2QQ, UK

³Department of Psychology, University College London, London WC1H 0AP, UK

Abstract: Persistent vegetative state is arguably one of the least understood and most ethically troublesome neurological conditions in modern medicine. The term describes a rare disorder in which patients who emerge from coma appear to be awake, but show no signs of awareness. In recent years, a number of studies have demonstrated an important role for functional neuroimaging in the identification of residual cognitive function in patients meeting the clinical criteria for persistent vegetative state. Such studies, when successful, may be particularly useful where there is a concern about the accuracy of the diagnosis and the possibility that residual cognitive function has remained undetected. Unfortunately, functional neuroimaging in persistent vegetative state is extremely complex and subject to numerous methodological, clinical and theoretical difficulties. In this chapter, we argue that in order to most effectively define the degree and extent of preserved cognitive function in persistent vegetative state, a hierarchical approach to cognition is required. To illustrate this point, a series of functional neuroimaging paradigms in the auditory domain are described, which systematically increase in complexity in terms of the auditory and/or linguistic processes required and, therefore, the degree of preserved cognition that can be inferred from “normal” patterns of activation in persistent vegetative patients. Preliminary results in a small series of patients provide a strong basis for the systematic study of possible residual cognitive function in persistent vegetative state.

Introduction

The clinical features of persistent vegetative state were formally introduced into the literature by Jennett and Plum (1972) and later clarified and refined by the Multi-Society Task Force on Persistent Vegetative State (1994a, b) and the Royal College of Physicians (1996). Etiology is variable, although the condition may arise as a result of road traffic accident, ischemic attack, anoxia, en-

cephalitis or viral infection. A diagnosis of persistent vegetative state is not normally considered until between 1 and 3 months post ictus, at which point there must be no evidence of sustained, reproducible, purposeful or voluntary behavioral response to visual, auditory, tactile or noxious stimuli. There must also be no evidence of language comprehension or expression, although there is generally sufficiently preserved hypothalamic and brain stem autonomic functions to permit survival with medical care. Although persistent vegetative state often follows coma, it is characterized by an irregular but cyclic state of circadian sleeping and waking. In

*Corresponding author. Tel.: +44 (0) 1223 355 294 X511; Fax: +44 (0) 1223 359 062; E-mail: adrian.owen@mrc-cbu.cam.ac.uk

contrast, patients in coma present with eyes closed and lack any consistent sleep–wake cycles.

An accurate and reliable evaluation of the level and content of cognitive processing is of paramount importance for the appropriate management of patients diagnosed with persistent vegetative state. Objective behavioral assessment of residual cognitive function can be extremely difficult in these patients, as motor responses may be minimal, inconsistent, and difficult to document, or may be undetectable because no cognitive output is possible. In recent years, a number of studies have demonstrated an important role for functional neuroimaging in the identification of residual cognitive function in vegetative patients. Until recently, the majority of these studies used either fluorodeoxyglucose (FDG), positron emission tomography (PET) or single photon emission computed tomography (SPECT), and reported widespread reductions of up to 50% in (resting) cerebral blood flow and glucose metabolism (Levy et al., 1987; DeVolder et al., 1994; Tommasino et al., 1995). In some cases, however, isolated “islands” of metabolism have been identified in circumscribed regions of cortex, which may suggest residual cognitive processing in a subset of patients (see Schiff and Plum, 1999). While metabolic studies are useful in this regard, they can only identify functionality at the most general level; that is, mapping cortical and subcortical regions that are *potentially* recruitable, rather than relating neural activity within such regions to specific cognitive processes (Momose et al., 1989; Turkstra, 1995).

On the other hand, methods such as $H_2^{15}O$ PET and functional magnetic resonance imaging (fMRI) can be used to link residual neural activity to the presence of covert cognitive *function*. In short, functional neuroimaging, or the so-called “activation studies”, have the potential to demonstrate distinct and specific physiological responses (changes in regional cerebral blood flow or changes in regional cerebral haemodynamics) to controlled external stimulation in the absence of any overt response on the part of the patient. In the first of such studies, $H_2^{15}O$ PET was used to measure regional cerebral blood flow (rCBF) in a post-traumatic vegetative patient during an auditorily presented story told by his mother (de Jong et al.,

1997). Compared to non-word sounds, activation was observed in the anterior cingulate and temporal cortices, possibly reflecting emotional processing of the contents, or tone, of the mother’s speech. In another patient diagnosed as vegetative, Menon et al. (1998) also used PET, but to study covert *visual* processing in response to familiar faces. During “experimental” scans, the patient was presented with pictures of the faces of family and close friends, while during “control” scans scrambled versions of the same images were presented, which contained no meaningful visual information whatsoever. Previous imaging studies in healthy volunteers have shown that such tasks produce robust activity in the right fusiform gyrus, the so-called human “face area” (e.g. Haxby et al., 1991, 1994). The same visual association region was activated in the vegetative patient when the familiar face stimuli were compared to the meaningless visual images (Menon et al., 1998; Owen et al., 2002). In other cohort studies, both noxious somatosensory stimuli (Laureys et al., 2002) and auditory stimuli (Laureys et al., 2000; Owen et al., 2002; Boly et al., 2004) have also been shown to systematically activate appropriate cortical regions in patients meeting the clinical criteria for the vegetative state.

In all such studies, however, the choice of imaging paradigm poses a number of methodological, ethical and procedural problems. For example, as noted above, motor responses are often minimal, inconsistent or absent in patients with persistent vegetative state and, by definition, cannot be elicited directly (i.e. willfully) by external stimulation. In addition, even assuming that some level of residual cognitive processing does exist, there is no reliable mechanism for ensuring that the presented stimuli are actually *perceived* by the patient. Many persistent vegetative state patients suffer serious damage to auditory and/or visual input systems, which may impede performance of any “higher” cognitive functions (e.g. voice discrimination), which place demands on these “lower” sensory systems (e.g. hearing). Like patients with any form of serious brain damage, persistent vegetative state may also be accompanied by a significant reduction in attention span (assuming some level of cognitive processing remains), which may

further complicate the assessment of higher cognitive functions. Spontaneous movements during the scan itself may also compromise the interpretation of functional neuroimaging data, particularly scans acquired using fMRI. Where PET methodology is employed, issues of radiation burden must also be considered and may preclude longitudinal or follow-up studies in many patients. Finally, data processing of functional neuroimaging data may also present challenging problems in patients clinically diagnosed as persistent vegetative state. For example, the presence of gross hydrocephalus or focal pathology may complicate coregistration of functional data (e.g. acquired with PET or fMRI) to anatomical data (e.g. acquired using structural MRI), and the normalization of images to a healthy reference brain. Under these circumstances, statistical assessment of activation patterns is complex and interpretation of activation foci in terms of standard stereotaxic coordinates may be impossible.

A final problem concerns the extent to which functional neuroimaging data can, and should, be used as evidence of preserved *awareness* in patients meeting the clinical criteria for persistent vegetative state. While a number of recent studies have successfully identified islands of residual cognitive function in vegetative patients (e.g., de Jong et al., 1997; Menon et al., 1998; Laureys et al., 2000, 2002; Owen et al., 2002; Boly et al., 2004), invariably in such cases, the evidence for awareness of either self or the environment has been equivocal, at best. A plethora of data in healthy volunteers from studies of implicit learning and the effects of priming (see e.g., Schacter, 1994 for review) to studies of learning during anesthesia (e.g., Bonebakker et al., 1996) have demonstrated that many aspects of human cognition can go on in the absence of awareness. Thus, the fact that a normal response to face stimuli was observed in the patient described by Menon et al. (1998), for example, does not necessarily mean that the patient was *aware* during the procedure; in healthy volunteers, signal intensity changes have been observed in the fusiform gyrus in response to primed faces in the absence of conscious awareness (Henson et al., 2000).

In this chapter, we will argue that functional neuroimaging studies in patients meeting the clinical

criteria for persistent vegetative state should be conducted hierarchically; beginning with the simplest form of processing within a particular domain (e.g. auditory) and then progressing sequentially through more complex cognitive functions. By way of example, a series of auditory paradigms will be described that have all been successfully employed in functional neuroimaging studies of vegetative patients. These paradigms increase in complexity systematically from basic acoustic processing to more complex aspects of language comprehension and semantics. We suggest that such a hierarchy of cognitive tasks provides the most valid mechanism for defining the depth and breadth of preserved cognitive function in patients meeting the clinical criteria for persistent vegetative state, and discuss how such an approach might be extended to allow clear inferences about the level of “awareness” or consciousness to be made.

Acoustic processing

As noted above, many vegetative patients suffer serious damage to auditory and/or visual input systems, which may impede performance of all cognitive functions that place demands on these “lower” sensory systems. At the most basic level, therefore, it is important to establish normal or near-normal sensory perception in any candidate patient for functional neuroimaging studies of “higher” cognitive functions (e.g. language processing). For the most part, functional neuroimaging is not necessary in this regard; that is to say, the measurement of auditory or visual evoked potentials are usually sufficient to establish that the respective neural pathways are intact. The integrity of the auditory neural axis can be assessed using a number of tests including the brainstem auditory evoked response (BAER) and passive mismatch negativity (MMN). The BAER is typically elicited using broad band clicks presented through headphones and produces a series of seven waveforms recorded from the scalp during the first 12 ms following a click. These waveforms reflect post-synaptic activity along the initial length of the neural axis, including the eighth cranial nerve, pons and thalamic nuclei. In contrast,

the passive MMN test is one of the several long-latency auditory evoked potentials able to assess the integrity of the auditory cortex. The MMN is elicited following an infrequent change in a repetitive sound. This is usually a tone burst, such as a 1500 Hz deviant occurring among 1000 Hz standard tones, but can also be more complex auditory stimuli such as synthesized speech. Experimental evidence suggests that MMN (main component) is generated in the superior temporal cortex (Alho, 1995). It is widely thought to reflect a pre-cognitive response generated by comparing the deviant input with a neural memory trace encoding the physical features of the repetitive sound (Naatanen, 2003). The MMN has been successfully applied to the assessment of vegetative patients, although with considerable variability in results (Jones et al., 2000; Kotchoubey et al., 2001; Kotchoubey, this volume). The integrity of the visual neural pathway can be assessed in a similar way to the BAER. The post-synaptic response to transient visual stimuli, such as flashes from light emitting diodes (LED), can be recorded from the scalp using electrodes. In response to LED flashes, the visual cortex typically produces a series of three waveforms during the first 250 ms after the stimulus. These waveforms reflect post-synaptic activity in the lateral geniculate and striate areas of the visual cortex. However, although such investigations can be easily applied to vegetative patients using LED goggles, for example, this visual evoked potential is too crude to pinpoint most visual impairments and, where necessary, more detailed investigations using retinography or pattern reversal visual-evoked potentials should be employed.

Perceptual processing

Once basic neural responses to sounds have been established, it becomes possible to investigate whether the lesioned brain is able to discriminate between different categories of sound. Speech perception in healthy volunteers has been widely investigated within the functional neuroimaging literature and the findings have obvious clinical and therapeutic relevance for the investigation of

preserved cognitive function in vegetative patients. Most commonly, studies of speech perception involve volunteers being scanned while listening to binaurally presented spoken words (experimental condition), or signal correlated noise sounds (acoustic control condition), or no auditory stimulus at all (silence condition). For example, Mummery et al. (1999) used PET to scan six neurologically normal volunteers while they listened to concrete nouns or signal-correlated noise at a rate of 30 items per minute. The task instruction was to "pay attention to the stimuli without responding". When speech was compared with signal-correlated noise, they found a broad swathe of activation along both superior temporal gyri, extending ventrolaterally into the superior temporal sulcus (see Fig. 1, left panel).

The same paradigm has been applied recently to small numbers of patients meeting the clinical criteria for persistent vegetative state. For example, Owen et al. (2002) described the case of a 30-year-old female bank manager, who suffered severe head injuries during a road traffic accident involving a head-on collision with another vehicle (patient DE). During a significant period trapped in the car, she probably suffered a period of hypoxia with hypotension. The Glasgow Coma Scale at the scene of the accident indicated a score of 4/15 with no improvement post-resuscitation. A long stay in intensive care was accompanied by episodes of pupillary unreactivity on more than one occasion. Fourteen weeks *post ictus*, the pupils remained dilated and unreactive. The patient was weaned off the ventilator but still required a tracheotomy. Brainstem auditory evoked responses at the time were intact on the right but abnormal on the left. Computed tomography findings at admission revealed a left frontal sub-cortical hemorrhagic contusion and smaller fronto-parietal contusion. A small hemorrhage in the inter-peduncular fossa with low-density areas in adjacent midbrain-pons region were also observed. A repeat scan on the same day showed fresh midline hemorrhage in the anterior midbrain extending to posteromedial right thalamus. In addition, punctuate areas of high density in the right cerebellum and both cerebral hemispheres suggested diffuse axonal injury. The cerebral ventricles were noted to be normal in

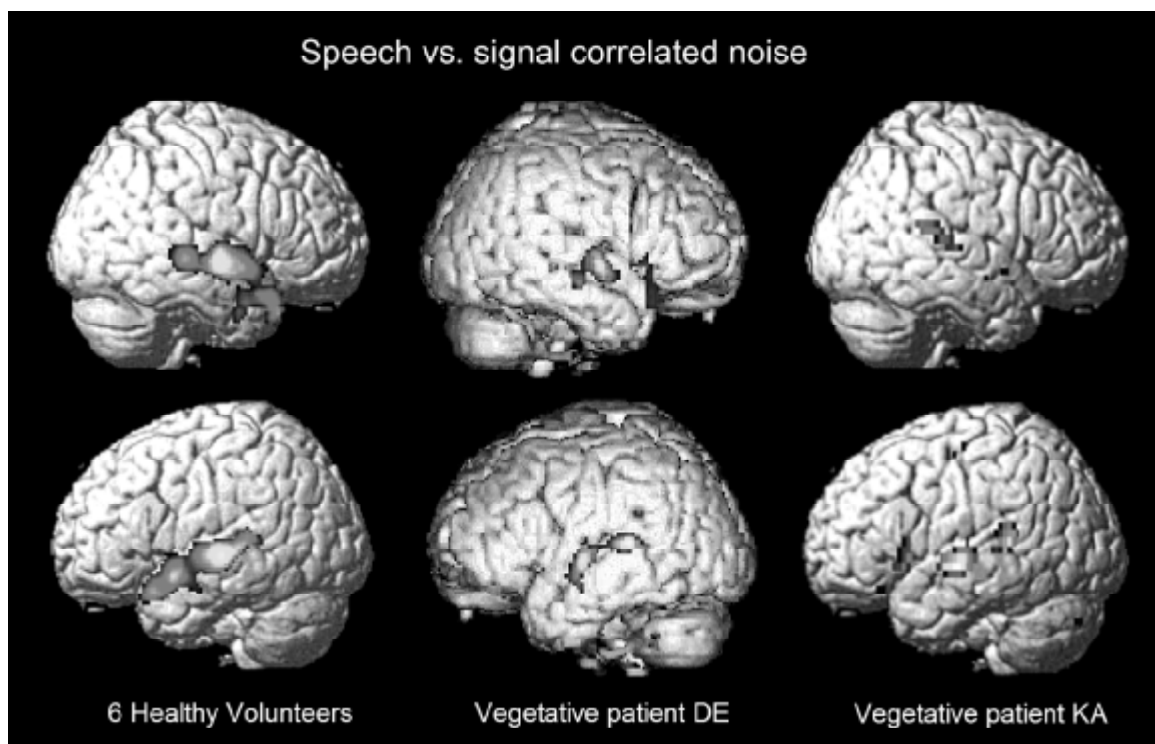


Fig. 1. PET data illustrating the comparison of speech with signal correlated noise. On the left, control data (adapted from Mummery et al., 1999), and on the right data from two patients meeting the clinical criteria for vegetative state. All data were pre-processed and analyzed using Statistical Parametric Mapping software (SPM99, Wellcome Department of Imaging Neuroscience, London, UK). See Plate 32.1 in Colour Plate Section.

size. Over several weeks the patient developed a withdrawal to pain but showed no consistent evidence of volitional activity.

The decision to use a PET auditory speech task was made largely on the basis of the partially intact brain auditory evoked responses. The patient was scanned while being presented binaurally with either spoken words (4 scans), signal correlated noise sounds (4 scans) or no auditory stimulus at all (4 scans). The presented words were disyllabic nouns matched for frequency (6–20,000), concreteness (400–700) and imageability (300–700) and were prerecorded on a tape by a speaker, rate being controlled by a metronome. The signal-correlated noise stimuli were made by selecting a sample of these spoken nouns with varying segmental durations and initial manners of articulation digitizing them, and then multiplying these with noise. The two sets of stimuli were matched for loudness by adjusting the amplification until they were subjectively similar. The task instruction given to the patient was to “pay attention to the stimuli without

responding” or, in the silence condition, just to rest. In both stimulus conditions, the words were presented at rates of 30 per minute and presentations were started 30 s prior to tracer infusion and continued until the end of data acquisition. The data were pre-processed and analyzed using Statistical Parametric Mapping software (SPM99, Wellcome Department of Imaging Neuroscience, London, UK).

In patient DE, the comparison of noise bursts with rest revealed significant foci of activation bilaterally in the auditory region, suggesting that basic auditory processes were at least somewhat functional. The comparison of speech sounds with noise bursts revealed significant rCBF increases on the superior temporal plane bilaterally and posterior to auditory cortex, in the region of the planum temporale, in the left hemisphere only (see Fig. 1, middle panel). The reverse subtraction yielded no significant foci of activation. These findings correspond extremely closely with the results described by Mummery et al. (1999), using the same

task in healthy volunteers (see Fig. 1). The same group have described similar findings in a second patient (patient KA) who also met the clinical criteria for persistent vegetative state (Owen et al., in press). In that study, a similar task was used and yielded an almost identical pattern of findings in the superior temporal lobe region when speech stimuli were compared with signal correlated noise (see Fig. 1, right panel).

Although, at first glance, activation in patients DE and KA appears to be rather less intense and less extensive than that observed in healthy volunteers (Mummery et al., 1999; see Fig. 1, left panel), this is probably not the case. While the normal data comprises 36 scans per condition, the two patients were scanned only four times in each condition, with a correspondingly lower chance of any voxel achieving significance. Given residual variations in normal structural and functional anatomy after spatial normalization, activation would be expected to be more extensive when averaged across several subjects than when measured in a single subject. When these factors are taken into account, the activation observed in both patients DE and KA is very similar to that seen in the group of healthy individuals.

In short, notwithstanding qualitative differences that are well within the range that would be expected given normal inter-subject variability, the pattern of activation observed in two vegetative patients during speech versus signal correlated noise contrasts is very similar to that observed in healthy awake control volunteers while performing the same tasks. Of course, recognising speech as speech does not imply anything about comprehension; that is, whether the *content* of the speech is understood or not (consider the experience of listening to a speaker talk in a foreign language of which you have no prior experience). To assess speech comprehension in persistent vegetative state it is necessary to move on to more complex experiment designs which tap aspects of *phonological* processing.

Phonological processing

While the results from studies of speech processing in vegetative patients (e.g., Owen et al., 2002; in

press; Boly et al., 2004), have suggested that some level of covert linguistic functioning may be preserved, such tasks do not allow any conclusions to be drawn about *comprehension*, i.e., whether speech is processed beyond the point at which it is identified as speech. One approach to this problem, which has met with some success, is to document responses to a set of stimuli of *graded complexity*. Crucially, assessment of shifts in the patient's pattern of activation to a standardized set of graded stimuli may provide a more comprehensive assessment of level of residual cognitive capacity, at least with reference to those processes recruited by the experimental task in question. Davis and Johnsrude (2003) have developed such a task using a test of graded intelligibility to look at speech comprehension. During the task, volunteers listen to sentences that have been distorted such that they produce a range of six levels of intelligibility (as measured by subsequent word report scores). In a parallel fMRI study, intelligibility (operationalized as "the amount of a sentence that is understood") was found to correlate with activation in a region of the left anterior and superior temporal lobe; as intelligibility increased, so did signal intensity in this region. This increase was also significantly positively correlated with word report scores; signal intensity increasing linearly as the subjects reported more words correctly. These findings in healthy volunteers suggest that activity in the left anterior and superior temporal lobe reflects processing of the linguistic content of spoken sentences (words and meanings), rather than their more general acoustic properties.

With this in mind, this auditory comprehension paradigm has been adapted recently for use with PET in vegetative patients (Owen et al., in press). From the test sentences used in a previous study (Davis and Johnsrude, 2003), 189 declarative English sentences, on a range of topics, comprising 5–17 words (1.7–4.3 s in duration) were taken. The same form of distortion (speech in noise) was generated by adding a continuous pink-noise background to these sentences at three signal-to-noise ratios (–1, –4 or –6 dB). This form of distortion disrupts both the spectral and temporal properties of speech, while preserving the duration, amplitude and overall spectral composition of the original.

There were three experimental conditions corresponding to the three signal-to-noise ratios used to generate these stimuli. The first condition, which is referred to as “high intelligibility”, had a signal-to-noise ratio of -1 dB (3 scans). The second “medium-intelligibility” condition had a signal-to-noise ratio of -4 dB (3 scans). The third “low-intelligibility” condition had a signal-to-noise ratio of -6 dB (3 scans).

Each scan comprised 21 declarative “speech in noise” sentences, with a 1 s gap between each sentence. The total time taken to play each trial was approximately 100 s. The study also contained a “silence” condition (also undertaken three times) during which no stimuli were presented.

Following the PET scan, the participants were asked to fill in a simple yes/no recognition form containing 10 sentences from each of the scans mixed up with 90 unheard “foil” sentences. As in the previous study, a linear relationship was observed between intelligibility and performance on the graded comprehension task (see Fig. 2).

Anecdotally, all of the subjects reported understanding “all” or “most” of the sentences in the high intelligibility condition; “some” of the sentences in the medium intelligibility condition and “hardly any”, “very little” or “none” of the sentences in the low intelligibility condition.

Subtraction of the silence condition from the three hearing conditions revealed significant activation along the superior and middle temporal gyri bilaterally. These results are entirely consistent

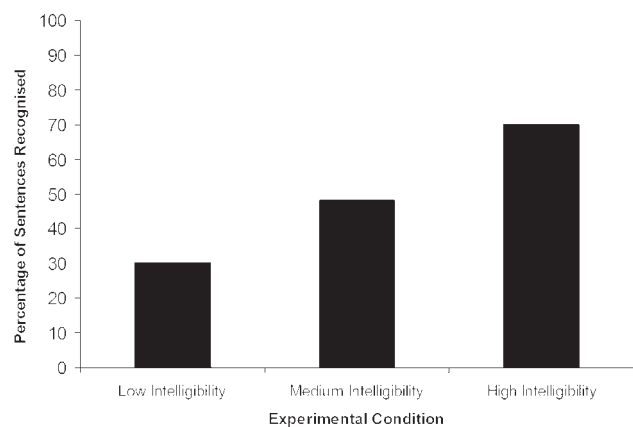


Fig. 2. The relationship between intelligibility and performance in healthy volunteers on the graded comprehension task.

with previous functional imaging studies investigating speech processing in healthy control subjects, in which activation has been found in the temporal cortex bilaterally, incorporating Heschel’s gyrus and the planum temporale (Mummery et al., 1999; Scott et al., 2000; Davis and Johnsrude, 2003).

Subtraction of the low intelligibility activation from high intelligibility activation revealed a significant rCBF increase in the anterior superior and middle temporal gyri (Brodmann’s areas 21 and 22) in the left hemisphere (Fig. 3, left). Analysis of blood flow values for the group across the three speech conditions revealed that rCBF values increased in this region as the sentences became more intelligible (Fig. 3, right). Thus, not only was there a linear relationship between behavioral responses and intelligibility (the higher the intelligibility of the sentences, the better able the participants were to recognize them after a short delay), but blood flow in this region also increased linearly as a function of increased intelligibility. Subtraction of the high intelligibility conditions from the low intelligibility conditions (the reverse subtraction) produced no significant areas of rCBF change.

One of the main aims of this study was to generate a task that can be used with vegetative patients. With this in mind, a case-by-case analysis was conducted in individual volunteers to ascertain the extent to which the group results were replicated in each individual. As these were individual and not group analyses, the threshold for reporting a peak as significant was reduced to $p < 0.01$, uncorrected for multiple comparisons. The results revealed that every one of the volunteers exhibited an increase in rCBF in response to increasing intelligibility of sentences within the left superior or middle temporal gyri (see Fig. 4), confirming that this region of cortex is sensitive to sentence intelligibility in individual volunteers. This finding is important because it suggests that the paradigm produces *consistent* blood flow responses in healthy volunteers. The reliability of any paradigm is paramount if it is to be used to detect residual cognitive functioning in patients in a vegetative state.

The same paradigm has been applied recently to small numbers of patients meeting the clinical

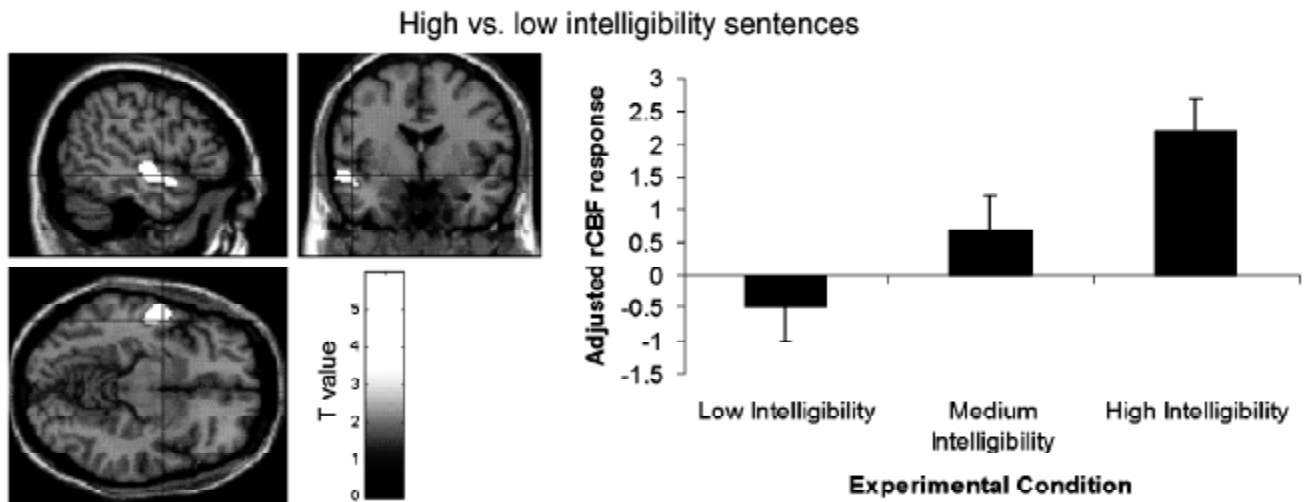


Fig. 3. Subtraction of the low intelligibility activation from high intelligibility activation in healthy volunteers reveals a significant rCBF increase in the anterior superior and middle temporal gyri (Brodmann’s areas 21 and 22) in the left hemisphere (left). Analysis of blood flow values for the group across the three speech conditions reveals that rCBF values increased in this region as the sentences become more intelligible (right). All data were pre-processed and analyzed using Statistical Parametric Mapping software (SPM99, Wellcome Department of Imaging Neuroscience, London, UK). Data presented are thresholded at $p < 0.05$ (corrected).

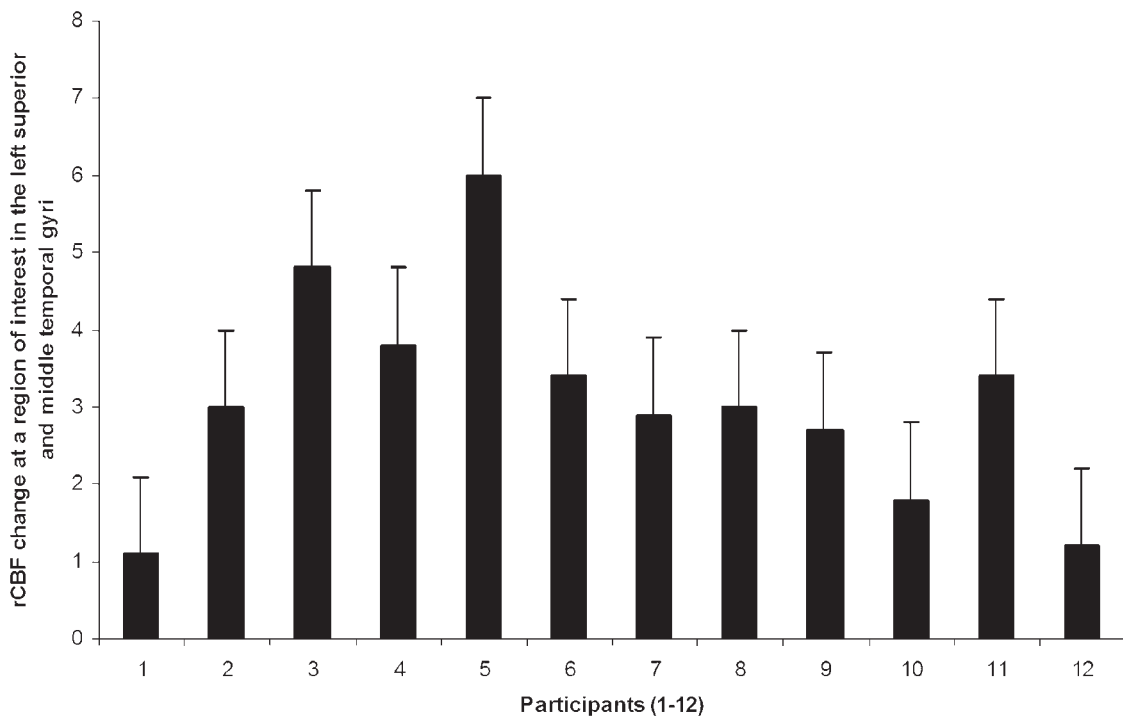


Fig. 4. Relative blood flow values for each healthy participant in the left anterior superior and middle temporal gyrus for the high intelligibility minus low intelligibility subtraction. For every participant there was an increase in blood flow in this location when the participants were listening to high intelligibility sentences relative to low intelligibility sentences.

criteria for persistent vegetative state. For example, Owen et al. (in press) described the case of a 30-year-old male (patient KA), who was diagnosed with basilar thrombosis and a posterior circulation infarction. In early June 2003, he collapsed with a severe headache and quickly became unresponsive. By the following day, he was drowsy, with a left partial Horner's syndrome, horizontal nystagmus, right hemiparesis and bilateral Babinski sign. An MRI revealed an infarction of the left pons, cerebellum and posterior thalamus. Consciousness fluctuated for the next few days until the patient became unconscious with absent doll's eye movement. At this stage, 1 week post ictus, angiography revealed severe basilar stenosis. Two recombinant tissue plasminogen activator infusions produced some improvement, although following a brief spell of partial recovery after the anesthesia had worn off, he deteriorated into a deep state of unconsciousness. Three weeks post ictus KA left the intensive care unit and to date he has not recovered. During the acute care period, a BAER and a passive MMN odd-ball paradigm were conducted. The BAER revealed preserved responses bilaterally from the pons and midbrain, although the onset of the midbrain component and consequently peak III–V interpeak interval were increased bilaterally. An MMN superior temporal N1 response was also observed, however an N2 discriminating response was absent. Following sequential multidisciplinary assessment a diagnosis of VS was made.

In October 2003, 4 months post ictus, a decision was made to investigate the possibility of residual cognitive functions using PET and the novel language intelligibility task described above. Nine months later an identical PET activation study was performed, both to assess the reproducibility of the technique and to establish whether there had been any significant deterioration in cortical activity. During the first PET study, the comparison of speech (collapsed across the three levels of intelligibility) with the silence baseline condition revealed significant foci of activation over the left and right superior temporal planes (see Fig. 5, top left), suggesting that basic auditory processes were probably functional.

With this in mind, a second comparison was made, comparing low intelligibility sentences with

high intelligibility sentences in order to isolate any residual activity related specifically to the comprehension of spoken language. This comparison revealed two peaks in the brain in the superior and middle temporal gyri of the left hemisphere (see Fig. 5, top right).

During the second PET study, 13 months post ictus, the comparison of speech (collapsed across the three levels of intelligibility) with the silence baseline condition revealed several foci of activation over the superior and middle temporal gyri of the left and right hemispheres (see Fig. 5, bottom left), suggesting again that basic auditory processes were probably still functional. The second comparison, comparing low intelligibility sentences with high intelligibility sentences, revealed two peaks in the brain in the superior and middle temporal gyrus of the left hemisphere (see Fig. 5, bottom right). In both comparisons, the activation foci are extremely close to those regions that were activated by the same comparison in the patient, 9 months earlier (see Fig. 5).

These findings have a number of important theoretical and clinical implications. First and foremost, it suggests that whatever level of residual cognitive activity existed in patient KA, it was persistent across time and remains, at least until 13 months post ictus. Thus, the pattern of activation observed during the first PET study was both qualitatively and quantitatively similar to that observed 9 months later when an identical procedure was carried out. Although anatomical and global blood flow factors preclude direct statistical comparisons between the two sessions, examination of Fig. 5 reveals a startling similarity between the activation patterns observed in temporal-lobe auditory areas in both cases. Notwithstanding qualitative differences that are well within the range that would be expected given normal inter-subject variability, the pattern of activation observed in KA during both PET sessions was similar to that observed in healthy awake control volunteers while performing identical tasks.

Second, the results suggest that some level of speech comprehension is preserved in this patient. The region around the left superior and middle temporal gyrus is believed to be involved in the perception of intelligible spoken language

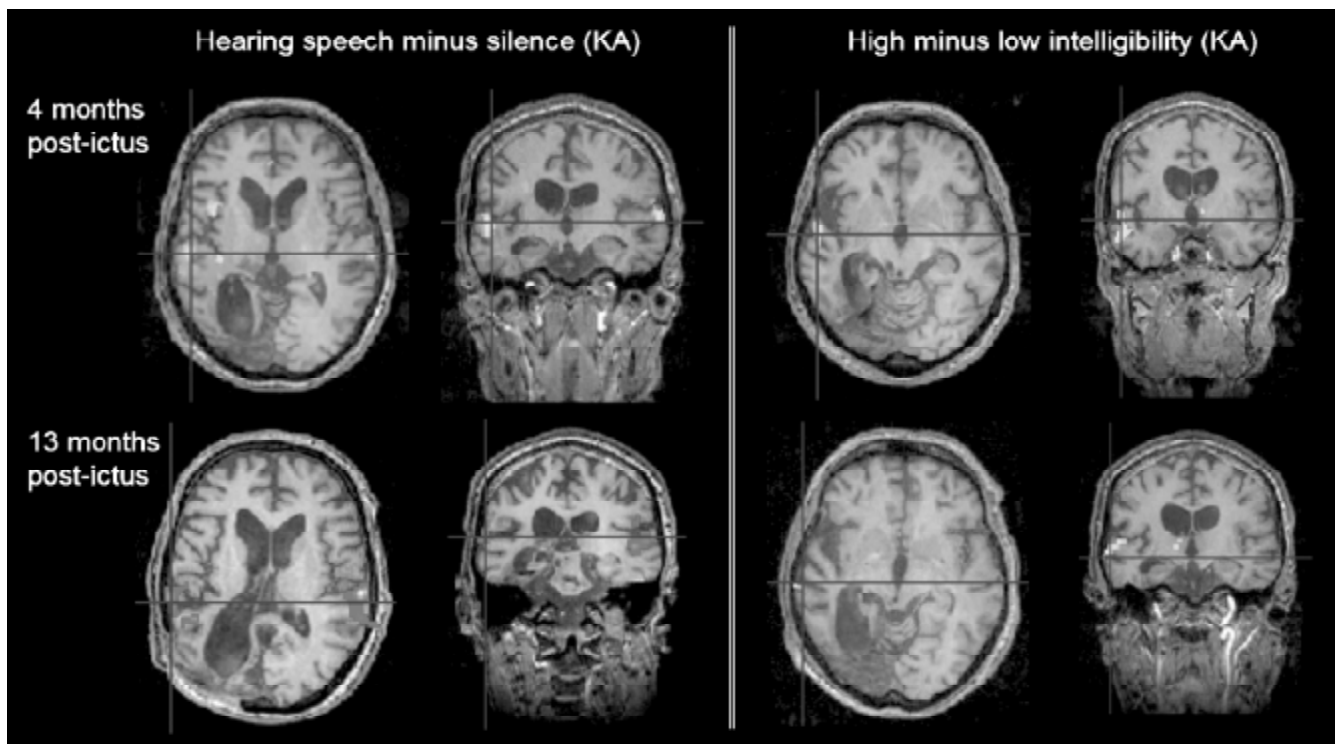


Fig. 5. Activation data from the two PET sessions, 9 months apart. (i) Hearing speech minus silence during the first PET session (top left) reveals activity bilaterally in the superior temporal gyrus. (ii) Hearing speech minus silence during the second PET session (bottom left) reveals very similar activity bilaterally in the superior temporal gyrus. (iii) High intelligibility speech minus low intelligibility speech during the first PET session (top right) reveals activity predominantly in the left superior temporal gyrus. (iv) High intelligibility speech minus low intelligibility speech during the second PET session (bottom right) reveals very similar activity predominantly in the left superior temporal gyrus. All data were pre-processed and analyzed using Statistical Parametric Mapping software (SPM99, Wellcome Department of Imaging Neuroscience, London, UK). See Plate 32.5 in Colour Plate Section.

(Binder et al., 2000; Scott et al. 2000). More specifically, it has been suggested that while the left superior temporal sulcus responds to the presence of phonetic information in general, its anterior part will only respond if the stimuli becomes intelligible (Scott et al., 2000). In the patient studied by Owen et al. (in press), activity in the left superior and middle temporal gyri was certainly focused *anteriorly* and in a region very similar to that activated in healthy volunteers when performing a formally identical task.

However, whether the responses observed reflect speech comprehension per se (i.e., understanding the contents of spoken language) or a more basic response to the acoustic properties of intelligible speech that distinguish it from less intelligible speech cannot be determined on the basis of these data alone.

Semantic processing

Understanding natural speech is ordinarily so effortless that we often overlook the complex computations that are necessary to make sense of what someone is saying. Not only must we identify all the individual words on the basis of the acoustic input, but we must also retrieve the meanings of these words and appropriately combine them to construct a representation of the whole sentence's meaning. When words have more than one meaning, contextual information must be used to identify the appropriate meaning. For example, for the sentence "The boy was frightened by the loud bark", the listener must work out that the ambiguous word "bark" refers to the sound made by a dog and not the outer covering of a tree. This process of selecting appropriate word meanings is

important because most words in English are ambiguous (Rodd et al., 2005). Therefore, selecting appropriate word meanings is likely to place a substantial load on the neural systems involved in computing sentence meanings.

Recently, an fMRI study in healthy volunteers has used this phenomenon to identify the brain regions that are involved in the semantic aspects of speech comprehension, in particular in the processes of activating, selecting and integrating contextually appropriate word meanings (Rodd et al., 2005). During the fMRI scan, the volunteers were played sentences containing two or more ambiguous words (e.g. “the *shell* was *fired* toward the *tank*”) and well-matched low-ambiguity sentences (e.g. “her secrets were written in her diary”). The ambiguous words were either homonyms (which have two meanings that have the same spelling and pronunciation; e.g. “bark”) or homophones (which have two meanings that have the same pronunciation but have different spelling; e.g. “knight”/“night”). While the two types of sentences have similar acoustic, phonological, syntactic and prosodic properties (and are rated as being equally natural), the high-ambiguity sentences require additional processing to identify and select contextually appropriate word meanings. An additional set of sentences that were matched for number of syllables, number of words and physical duration were converted into signal-correlated noise. These stimuli had the same spectral profile and amplitude envelope as the original speech, but since all spectral detail is replaced with noise they are entirely unintelligible and they were used as a low-level baseline condition.

Relative to low-ambiguity sentences, high-ambiguity stimuli produced increases in signal intensity in the left posterior inferior temporal cortex and inferior frontal gyri bilaterally (see Fig. 6, top panel).

The results of this study demonstrate that a key aspect of spoken language comprehension — the resolution of semantic ambiguity — can be used to identify the brain regions involved in the semantic aspects of speech comprehension (e.g. activating, selecting and integrating word meanings). Moreover, they support models of speech comprehension in which posterior inferior temporal regions are involved in semantic processing (Hickok and

Poeppel, 2000), and they demonstrate that the lateral inferior frontal gyrus, which has long been known to be important in syntactic processing of sentences and the semantic properties of single words, also plays an important role in processing the meanings of words in sentences. It is certainly striking that the comparison between these two sets of sentences that were rated as equally natural, and which differ only on a relatively subtle linguistic manipulation should produce such extensive activation differences. Further work is clearly needed to determine the precise function of the activated regions, but it is clear that they must form an important part of a neural pathway that processes the meaning of spoken language.

The same paradigm has been applied recently to small numbers of patients meeting the clinical criteria for persistent vegetative state. In one recent study, for example, Owen et al. (in press) used the test of semantic ambiguity to assess patient KA (described above) who had exhibited a normal pattern of PET activation in the graded complexity intelligibility task described above. The contrast between all the speech conditions (irrespective of ambiguity) plus the signal-correlated noise versus silence baseline yielded a pattern of activation very similar to the speech versus silence contrast of the initial PET investigation, although all of these changes were statistically significant using whole-brain methods of correction. Thus, large areas of activity were observed bilaterally in the superior temporal gyrus. When the combined high and low ambiguity sentences were compared to signal correlated noise, significant changes in signal intensity were again observed, bilaterally, in the superior temporal gyrus, a pattern which is again very similar to that observed in healthy volunteers (Rodd et al., 2005) and similar to that observed in the corresponding comparison of the PET study (Owen et al., in press).

When the high-ambiguity sentences were compared to the low-ambiguity sentences an ROI analysis based on the findings in healthy volunteers revealed responses in the patient that were well within the normal range in the left posterior inferior temporal region, but no consistent changes in the inferior frontal gyrus in either hemispheres (Fig. 6, bottom panel).

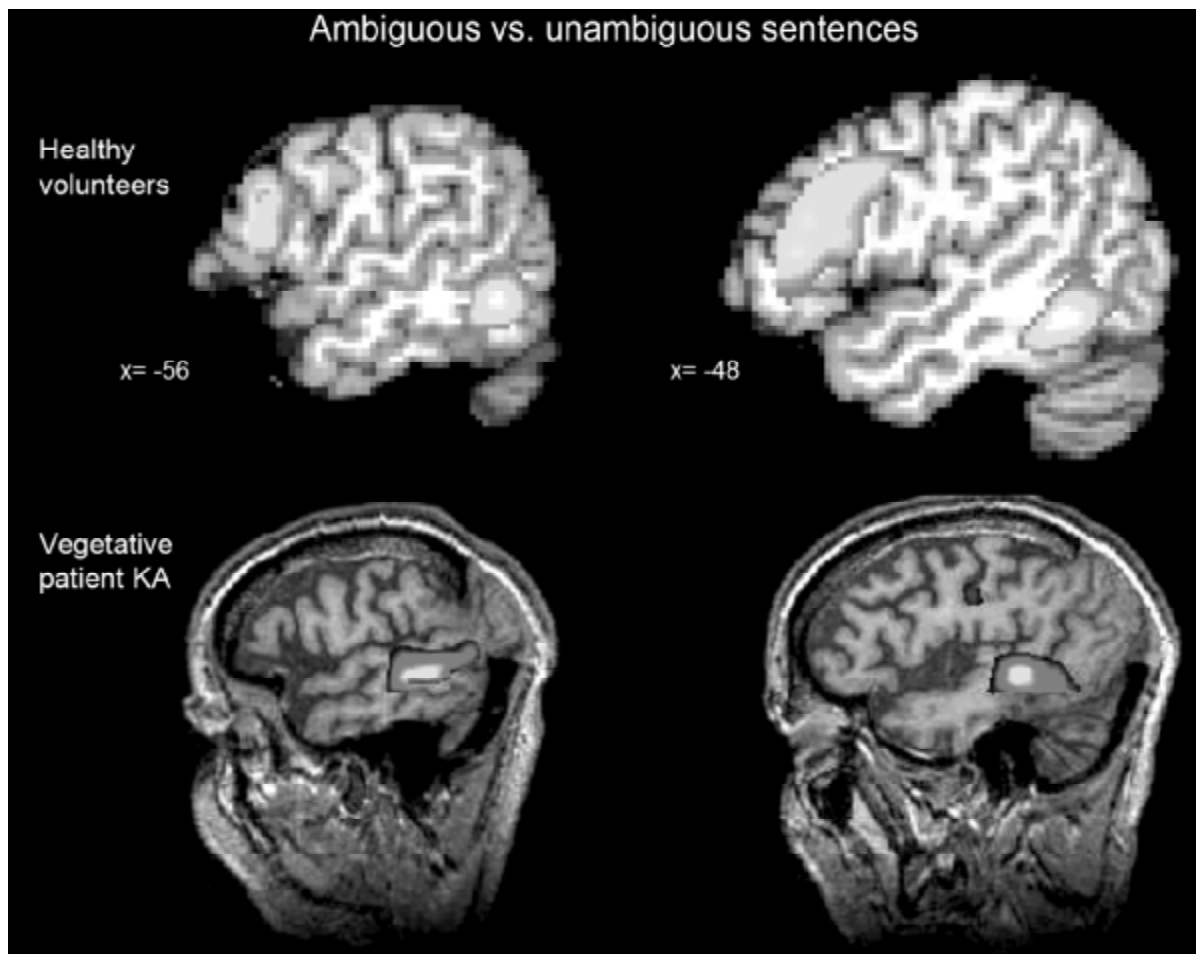


Fig. 6. fMRI data for the ambiguous sentences versus unambiguous sentences comparison. Like controls (top; adapted from Rodd et al., 2005), the patient (bottom) exhibited significant signal intensity changes in the left posterior inferior temporal cortex, but (unlike controls) not in the inferior frontal gyrus. All data were pre-processed and analyzed using Statistical Parametric Mapping software (SPM99, Wellcome Department of Imaging Neuroscience, London, UK). Data presented are thresholded at $p < 0.05$ (corrected). See Plate 32.6 in Colour Plate Section.

These results provide compelling evidence for high-level residual linguistic processing in a patient meeting the clinical criteria for vegetative state and suggest that some of the processes involved in activating, selecting and integrating contextually appropriate word meanings may be intact, despite his clinical diagnosis.

Discussion and conclusions

A number of recent studies have clearly demonstrated that functional neuroimaging has the potential to elicit distinct and specific physiological responses from patients meeting the clinical criteria

for persistent vegetative state, in the absence of any overt behavioral response. In this chapter we have attempted to illustrate the benefits of conducting such studies hierarchically; beginning with the simplest form of processing within a particular domain and then progressing sequentially through to more complex cognitive functions. This strategy, when applied to individual patients in a longitudinal manner, has the power to define the depth and breadth of preserved cognitive function in vegetative state. For example, in patient KA described recently (Owen et al., in press), clear conclusions could be drawn about the extent of residual function in the auditory domain at the perceptual, phonological and semantic levels. Thus, the imaging

data confirmed that the patient's brain was responding to something more complex than pure sound (as indexed by the significantly increased activity in response to speech relative to signal correlated noise), suggesting that some component of the *perception* of speech was relatively preserved. Second, the fact that a significant response was observed to speech of increasing intelligibility suggests that these perceptual processes are recruited more strongly for speech that can be more readily understood. These results could be interpreted as suggesting that *comprehension* may also have been relatively preserved in KA. One piece of evidence that supports this final conclusion was the observation that ambiguous sentences yielded a significant response, showing that some *semantic* aspect of sentences can alter neural activity; in other words, not only did the patient's brain recognize speech as speech, but it was also being processed at a level sufficient to detect when words with multiple meanings were presented.

The question therefore arises as to whether the presence of "normal" activation indicates a level of "awareness" in patient KA and in similar cases where preserved neural responses have been described (e.g., de Jong et al., 1997; Menon et al., 1998; Laureys et al., 2000 and 2002; Owen et al., 2002; Boly et al., 2004). There is a wealth of data on healthy volunteers, from studies of implicit learning and the effects of priming (e.g., see Schacter, 1994 for review), to studies of learning during anesthesia (e.g. Bonebakker et al., 1996), that have demonstrated that many aspects of human cognition can go on in the absence of awareness. Even the semantic content of masked information can be primed to affect subsequent behavior without the explicit knowledge of the participant, suggesting that some aspects of semantic processing may occur without conscious awareness (Dehaene et al., 1998). Thus, the fact that a partially normal response to ambiguous sentences was observed in the patient described by Owen et al. (in press), does not necessarily imply that the patient was *aware* during the procedure. However, without direct evidence (i.e. using exactly the same task) to the contrary it remains a possibility, and establishing whether changes in signal intensity related to semantic ambiguity can be elicited in other

situations in which sentences are known not to be consciously perceived (e.g. during sleep) remains a critical issue for future investigations with healthy volunteers (see Kotchoubey, this volume).

It remains to be seen, therefore, whether any functional neuroimaging paradigm can unequivocally demonstrate a level of preserved conscious awareness in a patient meeting the clinical criteria for persistent vegetative state. In our opinion, this issue will only be addressed directly using tasks that tap volitional (or consciously "willed") aspects of behavior. In all of the examples discussed above, from face processing to speech perception and even the detection of semantic ambiguous sentences, under normal circumstances cognitive processing is relatively *automatic*. That is to say, it occurs without the need for willful intervention on the part of the patient (you cannot choose to *not* recognize a face as a face, or to *not* understand speech that is presented clearly in your native language). In fact, this was an important factor in the choice of paradigms for study in these patients; persistent vegetative state, like any form of serious brain damage, may be accompanied by a significant reduction in attention span and an increased susceptibility to fatigue, either of which may mask positive findings if the chosen task is too demanding of depleted resources.

Notwithstanding this important consideration, a number of recent functional neuroimaging studies in healthy volunteers have described robust and anatomically specific changes in signal intensity at the single-subject level during tasks that unequivocally require "willed action" for their completion. For example, in one recent event-related fMRI study (Dove et al., submitted), conditions requiring volunteers to simply look at pictures of abstract art were compared with conditions in which they were explicitly instructed to remember similar stimuli for later retrieval. Looking, with no explicit instruction to remember was associated with significant increases in signal intensity in the medial temporal lobe, but not in a region of the mid-ventrolateral prefrontal cortex that has previously been implicated in memory encoding and retrieval. When the task instructions were changed subtly to encourage the volunteers to remember the stimuli, significant increases in signal intensity were observed bilaterally,

in the mid-ventrolateral frontal cortex, with no concomitant increase within the medial temporal-lobe region. Of the 20 volunteers scanned, 14 showed this effect to a level of corrected significance, while in three non-significant activation was observed in the appropriate regions of the brain. Importantly, because the only difference between the conditions that elicited frontal-lobe activation and those that did not, was in the instruction given *prior* to each trial, the activation observed can only reflect the *intentions* of the volunteer (which were, of course, based on the remembered instruction), rather than some altered property of the outside world. In this sense, the decision to “remember” rather than simply “attend” is an act of willed intention and, therefore, clear evidence for awareness of self and surroundings in these healthy volunteers. In this respect, if the same task were to yield positive results in a patient meeting the clinical criteria for persistent vegetative state, it would have to be argued that a similar level of conscious awareness was present. Of course, *negative* findings under the same circumstances could not (and should not) be used as evidence for lack of awareness; false-negative findings in functional neuroimaging studies are not uncommon, and in the example given above 15% of the healthy volunteers did not show the predicted pattern of signal intensity changes despite (presumably) being fully aware throughout the experimental procedure.

In summary, there is a clear need to improve our characterization of the clinical syndrome of persistent vegetative state, not only to redefine diagnosis, but also to stratify patients in terms of prognosis and possible responses to novel therapies that may emerge in the future. The use of functional neuroimaging in this context will clearly continue to present logistic and procedural problems. However, the detection and elucidation of residual cognitive function in this group of patients has such major clinical and scientific implications that such an effort is clearly justified.

References

- Alho, K. (1995) Cerebral generators of the mismatch negativity (MMN) and its magnetic counterpart (MMNm) elicited by sound changes. *Ear Hearing*, 1: 38–50.
- Binder, J.R., Frost, J.A., Hemmeke, T.A., Bellgown, P.S.F., Springer, J.A., Kaufman, J.N. and Possing, E.T. (2000) Human temporal lobe activation by speech and nonspeech sounds. *Cerebral Cortex*, 10: 512–528.
- Boly, M., Faymonville, M.E., Peigneux, P., Lambermont, B., Damas, P., Del Fiore, G., Degueldre, C., Franck, G., Luxen, A., Lamy, M., Moonen, G., Maquet, P. and Laureys, S. (2004) Auditory processing in severely brain injured patients: differences between the minimally conscious state and the persistent vegetative state. *Arch. Neurol.*, 61: 233–238.
- Bonebakker, A., Bonke, B., Klein, J., Wolters, G., Stijnen, T., Passchier, J. and Merikle, P.M. (1996) Information processing during general anaesthesia: evidence for unconscious memory. In: Bonke B., Bovill J.G.W. and Moerman N. (Eds.), *Memory and Awareness in Anaesthesia*. Swets and Zeitlinger, Lisse, Amsterdam, pp. 101–109.
- de Jong, B., Willemsen, A.T. and Paans, A.M. (1997) Regional cerebral blood flow changes related to affective speech presentation in persistent vegetative state. *Clin. Neurol. Neurosurg.*, 99: 213–216.
- Davis, M.H. and Johnsrude, I.S. (2003) Hierarchical processing in spoken language comprehension. *J. Neurosci.*, 23(8): 3423–3431.
- Dehaene, S., Naccache, L., Le Clec’h, G., Koechlin, E., Mueller, M., Dehaene-Lambertz, G., Van De Moortele, P.F. and Le Bihan, D. (1998) Imaging unconscious semantic priming. *Nature*, 395: 597–600.
- DeVolder, A.G., Michel, C., Guerit, J.M., Bol, A., Georges, B., Debarsy, T. and Laterre, C. (1994) Brain glucose metabolism in postanoxic syndrome due to cardiac arrest. *Acta Neurologica Belgica*, 94: 183–189.
- Dove, A., Brett, M., Cusack, R. and Owen, A. M. Frontohippocampal contributions to human memory: the role of intention. Submitted.
- Haxby, J.V., Grady, C.L., Horwitz, B., Ungerleider, L.G., Mishkin, M., Carson, R.E., Herscovitch, P., Schapiro, M.B. and Rapoport, S.I. (1991) Dissociation of object and spatial visual processing pathways in human extrastriate cortex. *Proc. Nat. Acad. Sci. USA*, 88: 1621–1625.
- Haxby, J.V., Horwitz, B., Ungerleider, L.G., Maisog, J.M., Pietrini, P. and Grady, C.L. (1994) The functional organization of human extrastriate cortex: a PET-rCBF study of selective attention to faces and locations. *J. Neurosci.*, 14: 6336–6353.
- Henson, R., Shallice, T. and Dolan, R. (2000) Neuroimaging evidence for dissociable forms of repetition priming. *Science*, 287: 1269–1272.
- Hickok, G. and Poeppel, D. (2000) Towards a functional neuroanatomy of speech perception. *Trends Cogn. Sci.*, 4: 131–138.
- Jennett, B. and Plum, F. (1972) Persistent vegetative state after brain damage. *Lancet*, 1: 734–737.
- Jones, S.J., Vaz Pato, M., Sprague, L., Stokes, M., Munday, R. and Haque, N. (2000) Auditory evoked potentials to spectrotemporal modulation of complex tones in normal subjects and patients with severe brain injury. *Brain*, 123: 1007–1016.
- Kotchoubey, B., Lang, S., Baales, R., Herb, E., Maurer, P., Mezger, G., Schmalohr, D., Bostanov, V. and Birbaumer, N. (2001) Brain potentials in human patients with extremely severe diffuse brain damage. *Neurosci. Lett.*, 301: 37–40.

- Laureys, S., Faymonville, M.E., Degueldre, C., Fiore, G.D., Damas, P., Lambermont, B., Janssens, N., Aerts, J., Franck, G., Luxen, A., Moonen, G., Lamy, M. and Maquet, P. (2000) Auditory processing in the vegetative state. *Brain*, 123: 1589–1601.
- Laureys, S., Faymonville, M.E., Peigneux, P., Damas, P., Lambermont, B., Del Fiore, G., Degueldre, C., Aerts, J., Luxen, A., Franck, G., Lamy, M., Moonen, G. and Maquet, P. (2002) Cortical processing of noxious somatosensory stimuli in the persistent vegetative state. *Neuroimage*, 17(2): 732–741.
- Levy, D.E., Sidtis, J.J. and Rottenberg, D.A. (1987) Differences in cerebral blood flow and glucose utilisation in vegetative versus locked-in patients. *Ann. Neurol.*, 22: 673–682.
- Menon, D.K., Owen, A.M., Williams, E.J., Kendall, I.V., Downey, S.P.M.J., Minhas, P.S., Allen, C.M.C., Boniface, S., Antoun, N. and Pickard, J.D. (1998) Cortical processing in the persistent vegetative state revealed by functional imaging. *Lancet*, 352: 200.
- Momose, T., Matsui, T., Kosaka, N., Ohtake, T., Watanabe, T., Nishikawa, J., Abe, K., Tanaka, J., Takakura, K. and Iio, M. (1989) Effect of cervical spinal cord stimulation (cSCS) on cerebral glucose metabolism and blood flow in a vegetative patient assessed by positron emission tomography (PET) and single photon emission tomography (SPECT). *Radiat. Med.*, 7: 243–246.
- Multi-Society Task Force on PVS. (1994a) Medical aspects of the persistent vegetative state (first part). *New Engl. J. Med.*, 330: 1400–1508.
- Multi-Society Task Force on PVS. (1994b) Medical aspects of the persistent vegetative state (second part). *New Engl. J. Med.*, 330: 1572–1579.
- Mummery, C.J., Ashburner, J., Scott, S.K. and Wise, R.J.S. (1999) Functional neuroimaging of speech perception in six normal and two aphasic subjects. *J. Acoust. Soc. Amer.*, 106: 449–456.
- Naatanen, R. (2003) Mismatch negativity: clinical research and possible applications. *Inter. J. Psychophys.*, 48: 179–188.
- Owen, A.M., Menon, D.K., Johnsrude, I.S., Bor, D., Scott, S.K., Manly, T., Williams, E.J., Mummery, C. and Pickard, J.D. (2002) Detecting residual cognitive function in persistent vegetative state. *Neurocase*, 8: 394–403.
- Owen, A.M., Coleman, M.R., Menon, D.K., Johnsrude, I.S., Rodd, J.M., Davis, M.H. and Pickard, J.D. Residual auditory function in persistent vegetative state: a combined PET and fMRI study. *Neuropsych. Rehabil.*, in press.
- Rodd, J.M., Davis, M.H. and Johnsrude, I.S. (2005). The neural mechanisms of speech comprehension: fMRI studies of semantic ambiguity. *Cerebral Cortex* Jan 5; [Epub ahead of print].
- Royal College of Physicians Working Group. (1996) The permanent vegetative state. *J. Roy. Coll. Physic. London*, 30: 119–121.
- Schacter, D.L. (1994) Priming and multiple memory systems: Perceptual mechanisms of implicit memory. In: Schacter D.L. and Tulving E. (Eds.), *Memory Systems*. MIT Press, Cambridge, MA, pp. 233–268.
- Schiff, N.D. and Plum, F. (1999) Cortical function in the persistent vegetative state. *Trend. Cogn. Sci.*, 3(2): 43–44.
- Scott, S.K., Blank, C., Rosen, S. and Wise, R.J.S. (2000) Identification of a pathway for intelligible speech in the left temporal lobe. *Brain*, 123: 2400–2406.
- Tommasino, C., Grana, C., Lucignani, G., Torri, G. and Fazio, F. (1995) Regional cerebral metabolism of glucose in comatose and vegetative state patients. *J. Neurosurg. Anesthesiol.*, 7: 109–116.
- Turkstra, L.S. (1995) Electrodermal response and outcome from severe brain injury. *Brain Injury*, 9(1): 61–80.